

# California M E D I C I N E

OFFICIAL JOURNAL OF THE CALIFORNIA MEDICAL ASSOCIATION  
© 1951, by the California Medical Association

Vol. 74

MAY 1951

No. 5

## Carcinoma of the Thyroid Gland

ROBERT S. POLLACK, M.D., *San Francisco*

### SUMMARY

*Sixty-three cases of cancer of the thyroid gland were studied. In 16 cases the cancer arose in an adenoma—without clinical evidence of carcinoma in any instance.*

*Hoarseness, dyspnea and dysphagia, fixation and hardness, and slow enlargement of the lateral lymph nodes were the most common diagnostic signs and symptoms.*

*The most common avenue of spread is the lymphatic system. In two-thirds of the cases in which metastasis occurred, the cervical nodes were involved.*

*Prognosis is related to the histologic type of the lesion.*

*Of 35 patients observed for five years after treatment, ten had no evidence of disease at the end of that time. Twenty were followed for ten years and four of them apparently were free of cancer.*

*The trend in treatment is toward more extensive surgical dissection. In inoperable cases, irradiation has been used with some benefit.*

THE wide differences in the clinical manifestations of cancer of the thyroid gland have created considerable divergence of opinion as to its true pathologic character and confusion as to proper treatment. The present study is based on 63 cases observed at the Stanford University Hospitals since 1921. Because of the variety of methods of treatment employed, with no one method predominant, statisti-

cal evaluation of results cannot be stressed. Rather, emphasis is put on the knowledge gathered on the course and development of the disease as related to the various histologic types, the location of cervical metastases, and the fate of patients with cancers that arose in simple adenomas.

### INCIDENCE

The percentage of cases in which nodular goiter becomes cancerous seems to vary from one part of the country to another.<sup>3, 4</sup> In Figure 1, the relative incidence reported in various parts of the United States is shown. The variations in figures are probably owing to the nature of the material studied, the small number of cases involved, and the tendency for patients with certain kinds of disease to gravitate to particular centers. Crile<sup>5</sup> noted that the surgical material studied represented a screened and selected incidence. Inaccuracy in classification of goiters adds to the confusion. Finally, autopsy material does not provide a true index. In the period 1944 to 1948, covered by Cole and co-workers,<sup>3</sup> there were 675 autopsies at the Illinois Research Hospital. In only two cases was thyroid cancer present. However, during this same period, 16 patients with thyroid cancer were operated upon. Of this number, 11 were known to be dead but autopsy was not done on any of them at the Illinois Research Hospital.

Carcinoma arising in diffuse toxic goiter is very rare,<sup>4, 10, 27</sup> and toxicity occurs infrequently in patients with thyroid cancer. When toxicity is present, as Friedell<sup>9</sup> has described, the carcinomatous area is not usually responsible for the hyperthyroidism.

In the present series of 63 cases of thyroid cancer, the growth arose from preexisting, clinically evident adenomas in 16 cases, or 25 per cent, an experience identical with that reported by other observers.<sup>3, 18, 21</sup>

From the Department of Surgery, Stanford University School of Medicine, San Francisco, California.

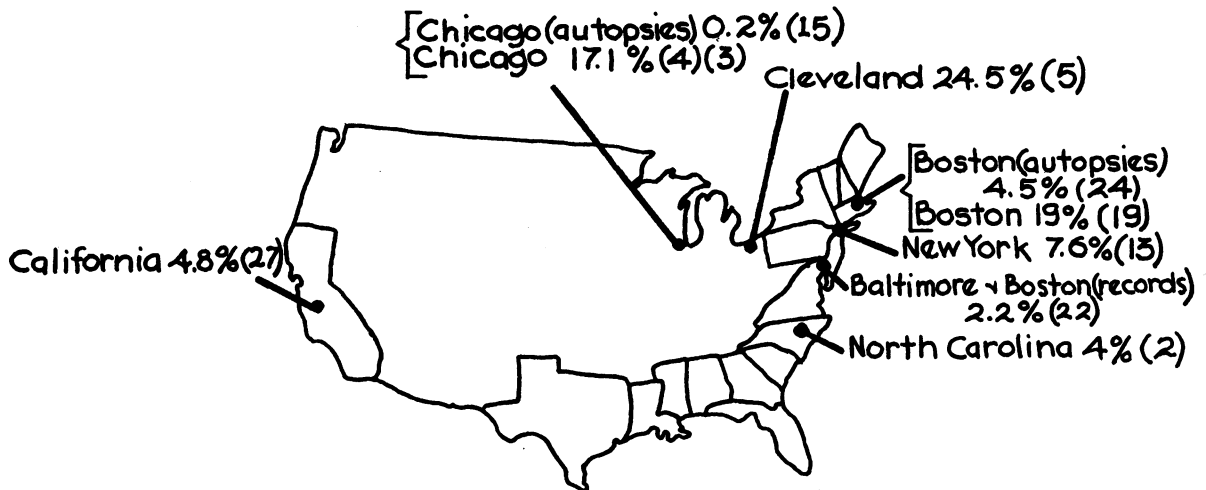


Figure 1.—Incidence of thyroid cancer in cases of nodular goiter in various areas of the United States. The figures are from surgical experience unless otherwise noted. The numbers in parentheses are reference numbers.

#### CLASSIFICATION

It is known that there are parallels between the morphologic pattern of thyroid tumors and the clinical manifestations associated with them and that the clinical picture varies with the type of tumor. The classification (Table 1) devised by Warren<sup>28</sup> and modified slightly by Means<sup>19</sup> and others,<sup>8,14</sup> enables the clinician to gauge the clinical course once the histologic nature of the lesion is known.

In some cases the clinical course associated with papillary tumor is extremely long, and as a consequence such tumors are considered of low grade malignancy. Papillary tumors occur most frequently in persons in the fourth and fifth decades of life. Thyroid cancers of youth and childhood are preponderantly papillary.

Certain tumors of the alveolar type are not diagnosed as cancer in pathologic examination of the operative specimen, owing to their extremely orderly structure. Months or years later a distant metastatic deposit may occur in a bone or elsewhere—a so-called "benign metastasizing struma."

Giant cell tumors of the thyroid gland are extremely malignant, and patients with this kind of tumor usually die soon. Frequently death is caused by obstruction of the trachea or esophagus, and, although visceral metastases occur, there is rarely time for them to develop. In the present series, two patients had giant cell tumors and died in three and six months respectively. The majority of patients had papillary adenocarcinoma.

#### METASTASES

Although thyroid cancers frequently invade the blood stream, the most common avenue of spread is through the lymphatic system. Lymph-borne metastases occur first in the cervical and later in the mediastinal nodes. The cervical lymph nodes of predilection are those palpated laterally, in the posterior triangle of the neck along the transverse cervical

TABLE 1.—Classification of Thyroid Cancer<sup>8, 14, 19, 28</sup>

- |  |   |
|--|---|
| I. <i>Low Grade or Potential Cancer:</i> |   |
| 1.                                       | Adenoma with blood vessel invasion.               |
| 2.                                       | Papillary cystadenoma with blood vessel invasion. |
| II. <i>Moderately Malignant:</i>         |   |
| 1.                                       | Papillary adenocarcinoma.                         |
| 2.                                       | Alveolar adenocarcinoma.                          |
| 3.                                       | Hürthle-cell adenocarcinoma.                      |
| 4.                                       | Solid adenocarcinoma.                             |
| III. <i>Highly Malignant:</i>            |   |
| 1.                                       | Small cell carcinoma (carcinoma simplex).         |
| 2.                                       | Giant cell carcinoma.                             |
| 3.                                       | Epidermal carcinoma.                              |
| 4.                                       | Fibrosarcoma.                                     |
| 5.                                       | Malignant lymphoma.                               |

chain, or the nodes of the middle and superior groups along the internal jugular vein. More rarely, metastases occur in nodes within the submaxillary triangle. In several cases metastasis to an axillary node has been observed. Three patients in the present series had such metastases in addition to spread to other sites.

There were 30 patients in the present series who had metastases when first observed. Of this number, 20 had metastases to the cervical nodes only. In 18 cases in which an accurate description of the nodal metastasis was given, ten patients had involvement of the transverse cervical group of nodes, seven of the middle and superior jugular groups, and one of the submaxillary triangle group.

In several cases in which cancer in laterally placed cervical lymph nodes was observed, a diagnosis of cancer arising in lateral aberrant thyroid tissue was erroneously made. After many years of study, it is now realized that the growths in those nodes are metastatic from a small, primary cancer tucked away in the thyroid gland, usually not palpable and not known to be present until the lobe is rotated out of its bed.

DIAGNOSIS

A fixed or hard tumor causing symptoms of pressure on the trachea or esophagus is usually cancer. The signs and symptoms most frequently noted in the present series were: Fixation, especially to the underlying trachea; hardness, often described as "stony hardness"; hoarseness, without soreness or pain; slow, asymptomatic enlargement of lateral lymph nodes; and later dyspnea and dysphagia (Table 2). A history of a long-standing solitary nodule which suddenly increases in size is significant. One patient reported that about six months

years, only one had a papillary tumor. One had an adenocarcinoma and two had unclassified carcinoma.

Because it is frequently stated that tumors of the thyroid gland may be present for years and therefore cannot be very malignant, particular attention was given the records of 23 patients with accurate histories showing the presence of a tumor two years or more before the first observation by a physician. Four of them were dead within a year, seven within two years. One patient had had a lump in the right lobe of the thyroid gland for 40 years. Only partial removal of the tumor was possible at operation. The pathologic diagnosis was papillary adenocarcinoma. Radioactive iodine and x-ray therapy were of no

TABLE 2.—Clinical Data on 63 Cases of Thyroid Cancer

Age: 30 cases were between 40 and 59 years; extreme, 6 to 86 years.	
Sex: 26 males; 37 females.	
Symptoms of toxic thyroid gland: 7 cases.	
Metastases (when observed on admission):	
Total cases .....	30
Cervical node .....	20
Skeletal and visceral.....	10
Recurrent tumor (following previous surgical treatment): 13 cases.	
Occurring as adenomas:	
Single .....	12
Multiple .....	4
Total.....	16
Diagnosed preoperatively: 32.	
Duration of tumor*—primary and/or metastatic (51 cases):	
Present less than 6 months.....	17
Present less than 12 months.....	27
Present less than 24 months.....	32

\* As determined from case history.

before she sought medical advice she noticed enlargement of a nodule which had been present for ten years. Six months after the first examination the patient died of widely disseminated metastases from a giant cell carcinoma of the thyroid.

RESULTS

The average five-year survival rate for patients with cancer of the thyroid gland is about 32 per cent,<sup>3</sup> although five-year survival rates below 10 per cent have been reported.<sup>7,29</sup> However, the slow growth of some of the tumors and the ten-year survival of patients with metastases compels abandonment of the "five-year cure" viewpoint in evaluating thyroid cancer.<sup>30</sup> The results in the present series are listed in Table 3. Twenty of the 44 patients who survived a year or more without disease had papillary adenocarcinoma, seven had adenocarcinoma, two had benign metastasizing struma (alveolar cell type), and ten had carcinoma of unclassified type (Chart 1). Of the ten patients who survived beyond five years without evidence of disease, five had papillary adenocarcinoma, two had adenocarcinoma and three had unclassified carcinoma. A significant observation is that of the four patients surviving ten

CHART 1

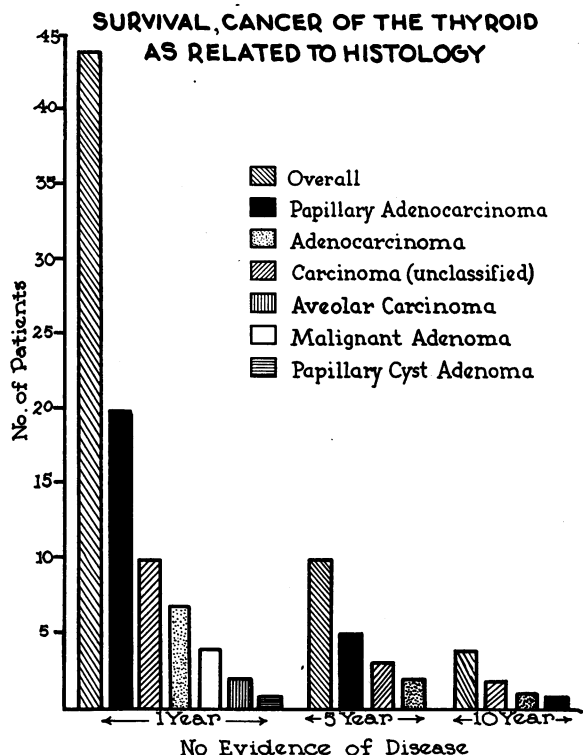


TABLE 3.—Results in 60 Cases of Cancer of the Thyroid Gland with Follow-up of One Year or More

Duration Follow-up (years)	No. Patients	NED*	AWD*	LTO*	DOC*	(Per cent) Det.†	(Per cent) Indet.†
1	60	44	4	0	1	73	80
3	41	18	3	1	1	44	49
5	35	10	0	1	1	29	34
10	20	4	0	2	1	20	35

\* Abbreviations: NED, no evidence of disease; AWD, alive with disease; LTO, lost to observation; DOC, died of other cause.

† Det. (Determinate): Known to be living without evidence of cancer. Indet. (Indeterminate): Assuming that patients lost to observation are still living, without evidence of cancer, and that those known to have died of other causes would have been free of cancer if they had lived to the end of the period indicated.

help. Eighteen months after the first examination the patient had widespread, painful metastases and obviously was in the terminal phase of the disease. Another patient had a thyroid tumor that had been present for 25 years. The report on a biopsy specimen was adenocarcinoma, but the tumor was deemed inoperable. Radioactive iodine, then x-ray therapy were given without benefit. A year after the first examination there was generalized metastasis and the patient was moribund. In another case, that of a woman who had had a goiter for 20 years, thyroidectomy was attempted but only subtotal removal could be accomplished. X-ray therapy was of no benefit. The pathologist reported anaplastic carcinoma. The patient died of cancer two months after the first examination.

In the total series of 63 patients, 24 died of cancer, 21 of them within five years. Seven more were alive, with cancer, at the time of this report and were expected to die within five years of the time they were first observed. Four patients died of other causes. Although in some cases patients may survive for relatively long periods, half of the patients in this series died or were expected to die within five years.

#### CANCER ARISING IN ADENOMAS

Many authorities contend that most thyroid cancers arise from nodular or adenomatous goiters.<sup>4,13,16,17,23</sup> However, the rapid, diffuse enlargement of the entire gland and the histologic features in some cases controvert that assumption. Pemberton<sup>21</sup> stated that the exact relationship is difficult to establish since the tumor may overgrow and obscure the original site of the cancer. Nevertheless, the relatively favorable results following adequate removal of cancer arising in an adenoma<sup>13,14</sup> as compared with the short survival of patients with the more diffuse tumors, suggests that there are two kinds of thyroid cancers. When the presence of cancer is obvious, the prognosis is poor. The highest survival rate is among patients with asymptomatic cancer within an adenoma. Much of the confusion in treatment and results springs from controversy in connection with such lesions. On the one hand it is stated that lesions of this kind are not true cancers, and on the other that the malignancy of such lesions is far underestimated.

Table 4 shows some of the clinical features and results in the 16 cases in this series in which cancer arose in a clinically evident adenoma.

#### TREATMENT

It is not possible to evaluate any one method of treatment on the basis of experience in the present series, but the trend is toward a more radical approach,<sup>3,8,16,17,26,29,31</sup> the ultimate being hemithyroidectomy (or total thyroidectomy if necessary) in continuity with radical neck dissection. Total lobectomy with frozen section rather than adenomectomy is recommended for solitary tumors. Not only will this remove a malignant tumor more adequately, but

it is felt that the presence of one adenoma often results in the formation of another within the same lobe, and the problem of recurrence has then to be dealt with. If the tumor is situated in the isthmus, a wide resection including one lobe or portions of both lateral lobes is advisable. Multiple adenomas are treated by total or near total thyroidectomy.

Neck dissection is reserved for use in cases in which the primary tumor has invaded the capsule, has involved the surrounding musculature, or has metastasized to cervical nodes. It includes removal of the internal jugular vein and sternocleidomastoid muscle and also (in view of metastasis to this area observed recently in several cases of thyroid cancer) dissection of the submaxillary triangle. The musculature overlying the involved lobe is removed in continuity with the contents excised in the neck dissection and lobectomy. In cases in which the growth is extensive it may be unwise to preserve the recurrent laryngeal nerve—better to sacrifice this structure in the interest of cleaner dissection.

There is by no means universal agreement upon this method of treatment. Crile<sup>5</sup> and Black<sup>1</sup> are not convinced that radical resection will add materially to the ultimate result. The problem of early invasion of veins is also to be considered, but the invasion of thyroid tumors into a vein may remain localized for a long time, a true embolus not forming for months or even years. The long survival of patients who have thyroid cancer with vein invasion is pertinent. The tendency for recurrent thyroid cancer to extend within veins and the need for wide and radical removal of the veins together with the tumor has been well stressed by Graham.<sup>11,12</sup>

If the tumor has grown into the thyroid cartilage on one side, removal of the cartilage is preferable to cutting across invaded tissue. As is known, thyroid cancer grows backward into the trachea and esophagus, but it should be pointed out that frequently these structures will be attached to the cancer, without actually being involved by it.<sup>16</sup> In an extensive neck operation requiring much dissection across the tracheal bed, tracheotomy at the close of the procedure is advisable.

#### RADIATION THERAPY

Although the treatment of thyroid cancer is primarily a surgical problem, radium and x-ray treatment can be effective against tumors of certain types, particularly papillary tumors. When the surgeon feels confident that no cancer remains following operation, there appears to be no reason for irradiation of the postoperative field as a prophylactic measure. If residual disease is present, accurate roentgen therapy to the diseased area has proved of help when given in large enough amounts. As such therapy, like any other, is not without sequelae, it should not be undertaken lightly. Surgical and x-ray treatment may be combined in otherwise hopeless cases for possible palliation. In the present series three patients who were treated with x-ray alone because they were deemed inoperable lived for three, four and five years respectively.

Radioactive iodine has given encouraging results in the treatment of toxic thyroid disease if the up-take of I<sup>131</sup> by the thyroid gland is large. Unfortunately, in only a few cases will the cancer pick up radioactive iodine, and even in those few the amount is often too small to be of therapeutic value. Apparently the faculty of up-take possessed by a normal or toxic thyroid gland is lost when carcinoma develops.<sup>3</sup> Except in an occasional case, therefore, radioactive iodine in its present form will contribute very little to the therapy of thyroid cancer.

450 Sutter Street.

REFERENCES

1. Black, B. M.: Surgical treatment of carcinoma of the thyroid gland, *Tr. Am. Assoc. Study of Goitre*, 1947, pg. 34.
2. Brenizer, H. G., and McKnight, R. B.: True adenomas and their relation to cancer, *Tr. Am. Assoc. Study of Goitre*, 1940, pg. 176.
3. Cole, W. H., Slaughter, D. P., and Rossiter, L. J.: The potential danger of nontoxic goitre, *J.A.M.A.*, 127:883, April 7, 1945.
4. Cole, W. H., Slaughter, D. P., and Majarakis, M. S.: Carcinoma of the thyroid gland, *Surg. Gynec. and Obst.*, 89:349, Aug. 1949.

5. Crile, G., Jr., and Dempsey, W. S.: Indications for removal of non-toxic nodular goitres, *J.A.M.A.*, 139:1247, April 30, 1949.
6. Crile, G., Jr.: Papillary carcinoma of the thyroid and lateral cervical region; so-called "lateral aberrant thyroid," *Surg. Gynec. and Obst.*, 85:757, Dec. 1947.
7. Dargent, M.: Indications et résultats du traitement chirurgical du cancer thyroïdien, *J. Chir. Par.*, 58:28, Jan. 1941.
8. Frazell, E. L., Foote, F. W.: The natural history of thyroid cancer, *J. of Clin. Endocrin.*, 9:1023, Dec. 1949.
9. Friedell, M. T.: Hyperthyroidism and adenocarcinoma of the thyroid gland, *Arch. Surg.*, 43:386, Sept. 1941.
10. Goetsch, E.: Incipient carcinoma occurring in exophthalmic goitre and originating in adenoma, *Tr. Am. Assoc. Study of Goitre*, 1940, pg. 191.
11. Graham, A.: Malignant epithelial tumors of the thyroid, *Surg. Gynec. and Obst.*, 39:781, Oct. 1924.
12. Graham, A.: Malignant tumors of the thyroid-epithelial types, *Ann. Surg.*, 82:30, July 1925.
13. Hinton, J. W., and Lord, J. W., Jr.: Is surgery indicated in all cases of nodular goitre, toxic and non-toxic?, *J.A.M.A.*, 129:605, October 27, 1945.
14. Horn, R. C., Jr., et al.: Carcinoma of the thyroid, *Ann. Surg.*, 126:140, Aug. 1947.
15. Jaffe, R. H.: Variation of weight of thyroid gland and frequency of its abnormal enlargement in region of Chicago, *Arch. Path.*, 10:887, Dec. 1930.

TABLE 4.—*Thyroid Cancer Arising in Adenoma—Studies of 16 Patients*

Sex	Solitary or Multiple	Diag. Made	Histology	Treatment	Neck Node Metastases	Results*
F	S	Surgically ?Clinically	Papillary adenocarcinoma	Partial thyroidectomy, x-ray, I <sup>131</sup>	—	AWD 2 yr.
F	S	Surgically	Carcinoma	Subtotal thyroidectomy, x-ray	—	DOD 2½ yr.
F	S	Surgically	Papillary adenocarcinoma	Subtotal thyroidectomy, right and left	—	NED 1 yr.
M	S	Surgically	Papillary adenocarcinoma	Subtotal thyroidectomy, right and left	—	NED 1 yr.
F	S	Surgically	Adenocarcinoma	Right lobectomy	—	NED 4 yr.
F	S	Surgically	Adenocarcinoma	Left lobectomy	—	NED 3 yr. then DOC.
F	S	Surgically ?Clinically	Malignant adenoma (Carcinoma)	Subtotal thyroidectomy	—	NED 9 yr.
F	S	Surgically	Malignant adenoma (Carcinoma)	Right lobectomy, plus attached node	+	NED 3½ yr.
F	S	Surgically	Papillary adenocarcinoma	Right lobectomy, partial left lobectomy	—	NED 3 yr.
F	S	Surgically ?Clinically	Papillary adenocarcinoma	Left lobectomy, subtotal right lobectomy	—	NED 3 mo.
F	S	Surgically	Papillary adenocarcinoma	Left lobectomy, local excision of nodes, lower and upper jugular chain	+	NED 3 yr.
F	S	Surgically	Giant cell carcinoma	Left lobectomy, x-ray	—	DOD 3 mo.
F	M	Surgically	Malignant adenoma (Carcinoma)	Subtotal thyroidectomy, right and left	—	NED 2½ yr.
F	M	Surgically	Papillary carcinoma	Subtotal thyroidectomy, right and left	—	LTO 1 mo.
F	M	Surgically	Papillary cyst adenocarcinoma	Subtotal thyroidectomy, right and left	—	NED 16 yr.
F	M	Surgically	Adenocarcinoma (metastatic struma)	(multiple) Adenomectomy	—	DOD 6 yr. 4 mo.

\* Abbreviations: NED, no evidence of disease; DOD, died of disease; AWD, alive with disease; LTO, lost to observation.

16. Lahey, F. H., Hare, H. F., and Warren, S.: Carcinoma of the thyroid, *Ann. Surg.*, 112:977, Dec. 1940.
  17. Lahey, F. H.: Carcinoma of the thyroid, *Am. J. Roentg. and Rad. Therapy*, 46:469, Oct. 1941.
  18. McSwain, B., and Diveley, W.: Malignant tumors of the thyroid gland, *Surg.*, 23:525, July 1948.
  19. Means, J. H.: *The Thyroid and Its Diseases*, Second Edition, 1948. J. B. Lippincott Co., pg. 453.
  20. Outerbridge, R. E.: Benign metastatic goitre, *Ann. Surg.*, 125:282, March 1947.
  21. Pemberton, J.: Malignant lesions of the thyroid gland, *Surg. Gynec. and Obst.*, 69:417, Oct. 1939.
  22. Rogers, W. F., Jr., Asper, S. P., Jr., and Williams, R. H.: Clinical significance of thyroid adenoma, *New Eng. J. Med.*, 237:569, October 16, 1947.
  23. Rouviere, H.: *Anatomie des Lymphatiques de L'Homme*, pg. 439, 1932, Masson et Cie., Editeurs, Paris, France.
  24. Schlesinger, M. J., Gargill, S. L., and Saxe, I. H.: Studies in nodular goitre, incidence of thyroid nodules in routine necropsies in non-goitrous regions, *J.A.M.A.*, 110:1638, May 14, 1938.
  25. VanderLaan, W. P.: Occurrence of carcinoma in autopsy material, *New Eng. J. Med.*, 237:221, August 14, 1947.
  26. Ward, G. E., Hendrick, J. W., Chambers, R. G.: Carcinoma of the thyroid gland, *Ann. Surg.*, 131:473, April 1950.
  27. Ward, R.: Malignant goitre, *Surg.*, 16:783, Nov. 1944.
  28. Warren, S.: The classification of tumors of the thyroid, *Am. J. Roentg. and Rad. Therapy*, 46:447, Oct. 1941.
  29. Watson, W. L., Pool, J. L.: Cancer of the thyroid, *Surg. Gynec. and Obst.*, 70:1037, June 1940.
  30. Wozencraft, P., and Foote, F. W.: Occult carcinomas of the thyroid, *Tr. of the Am. Assoc. Study of Goitre*, 1948, pg. 150.
  31. Personal communications.
- 